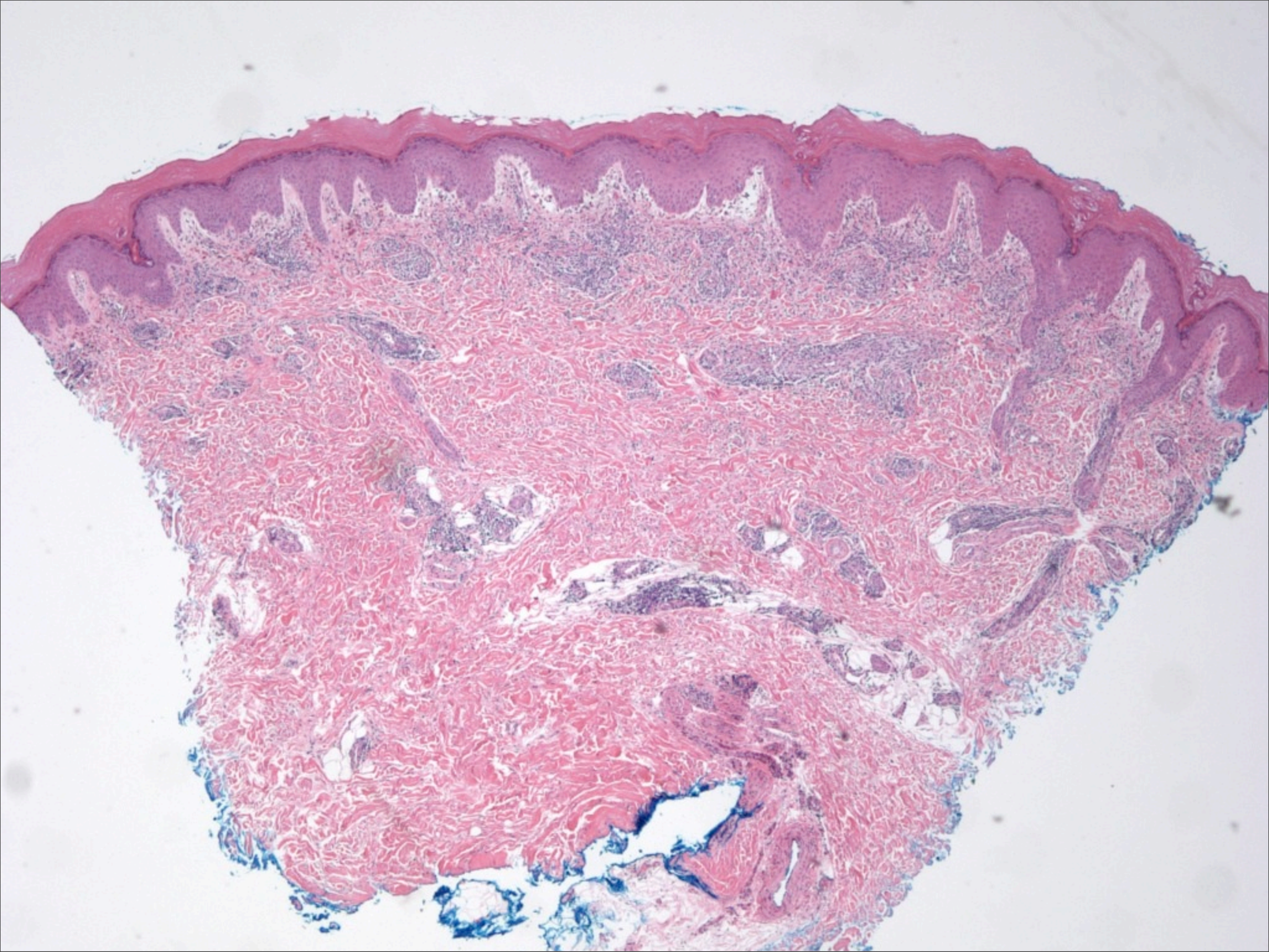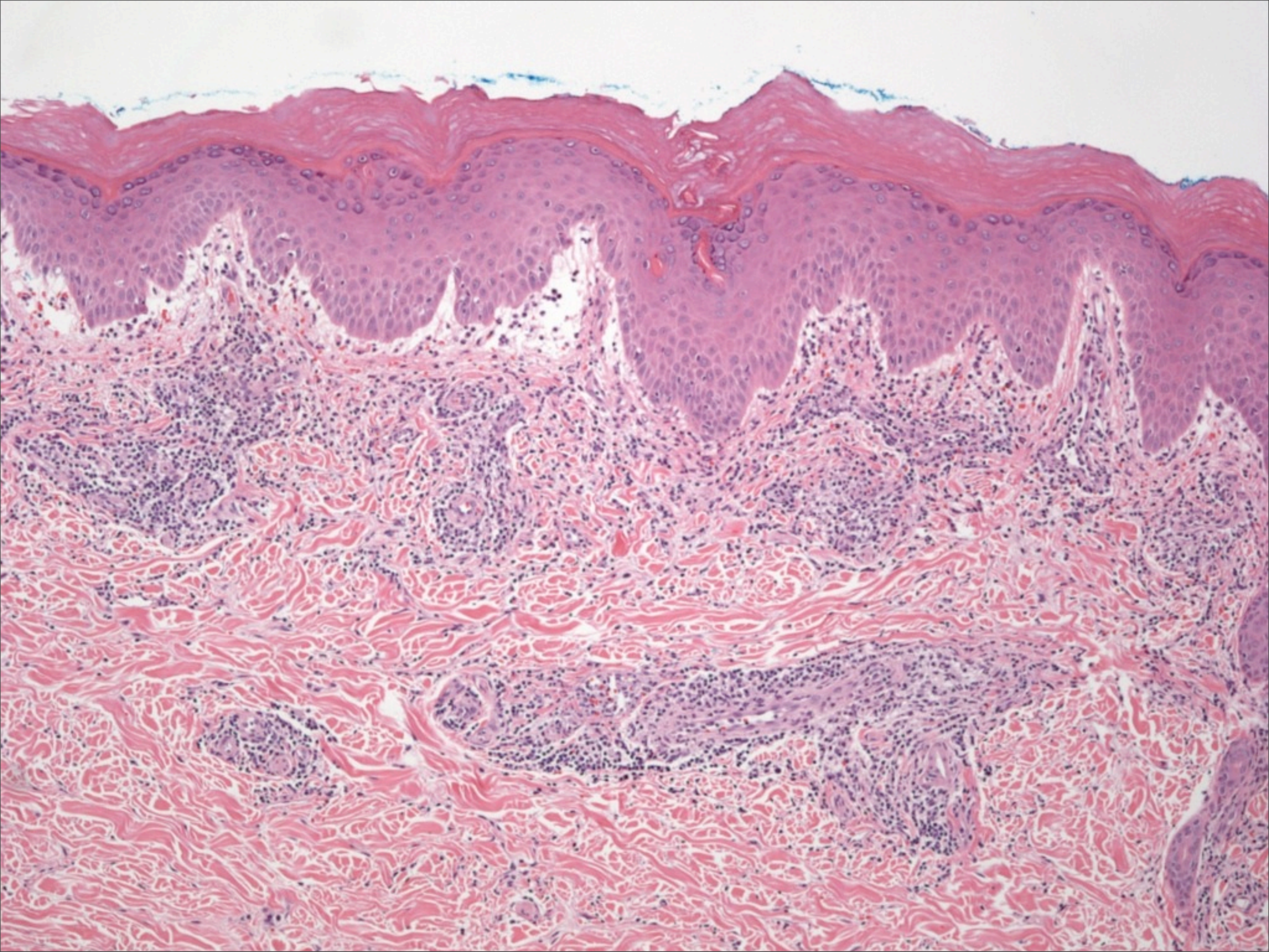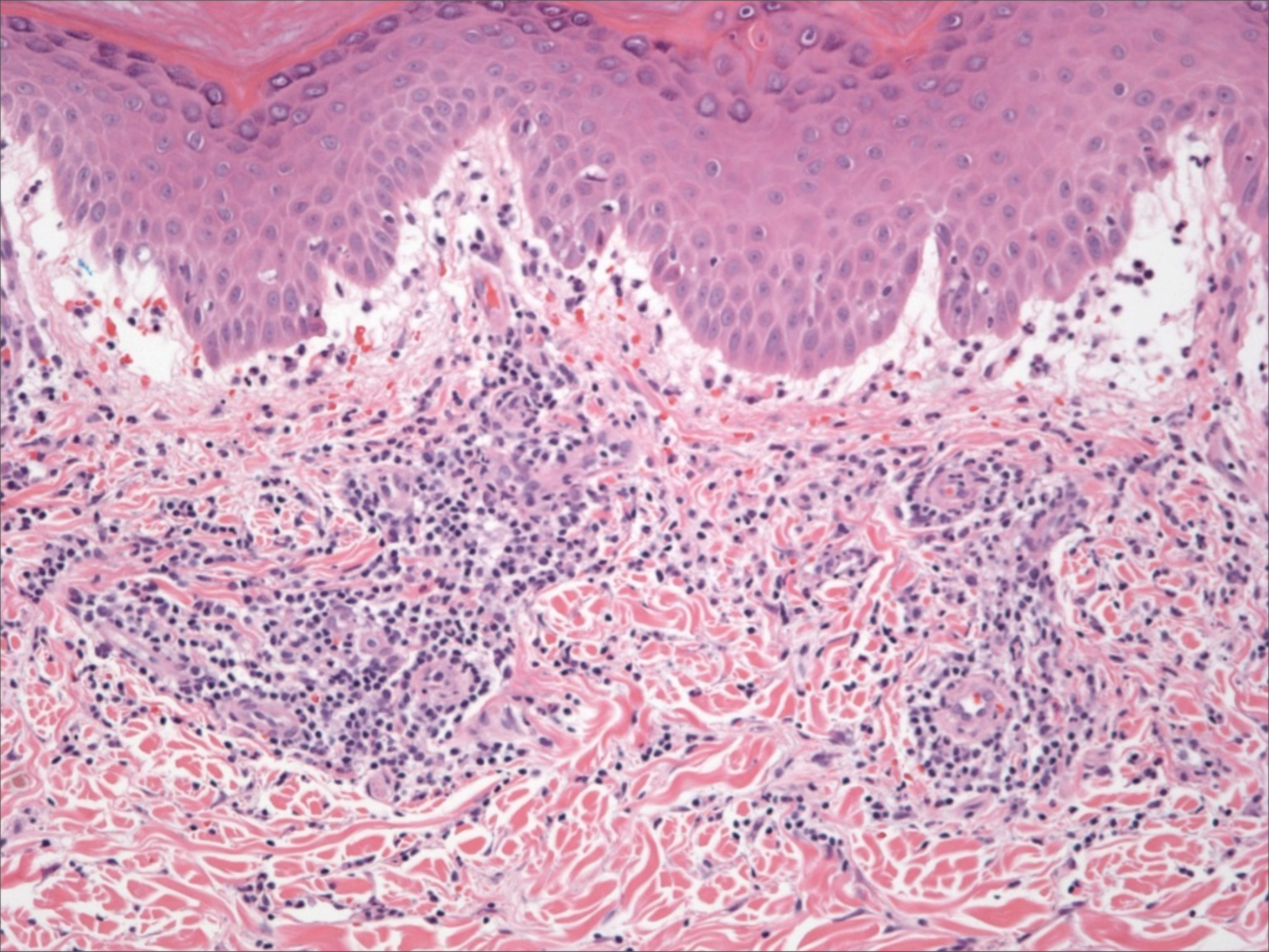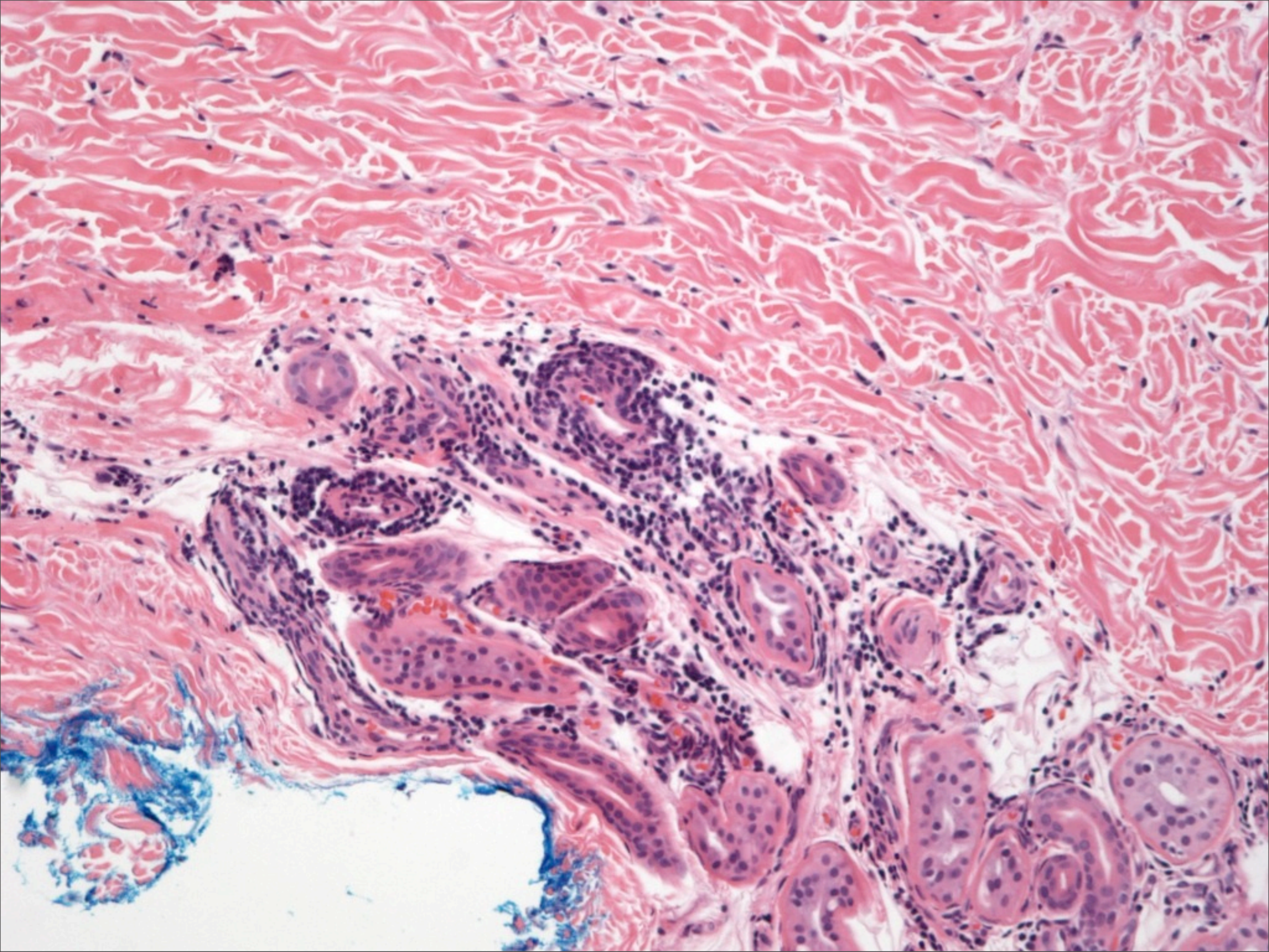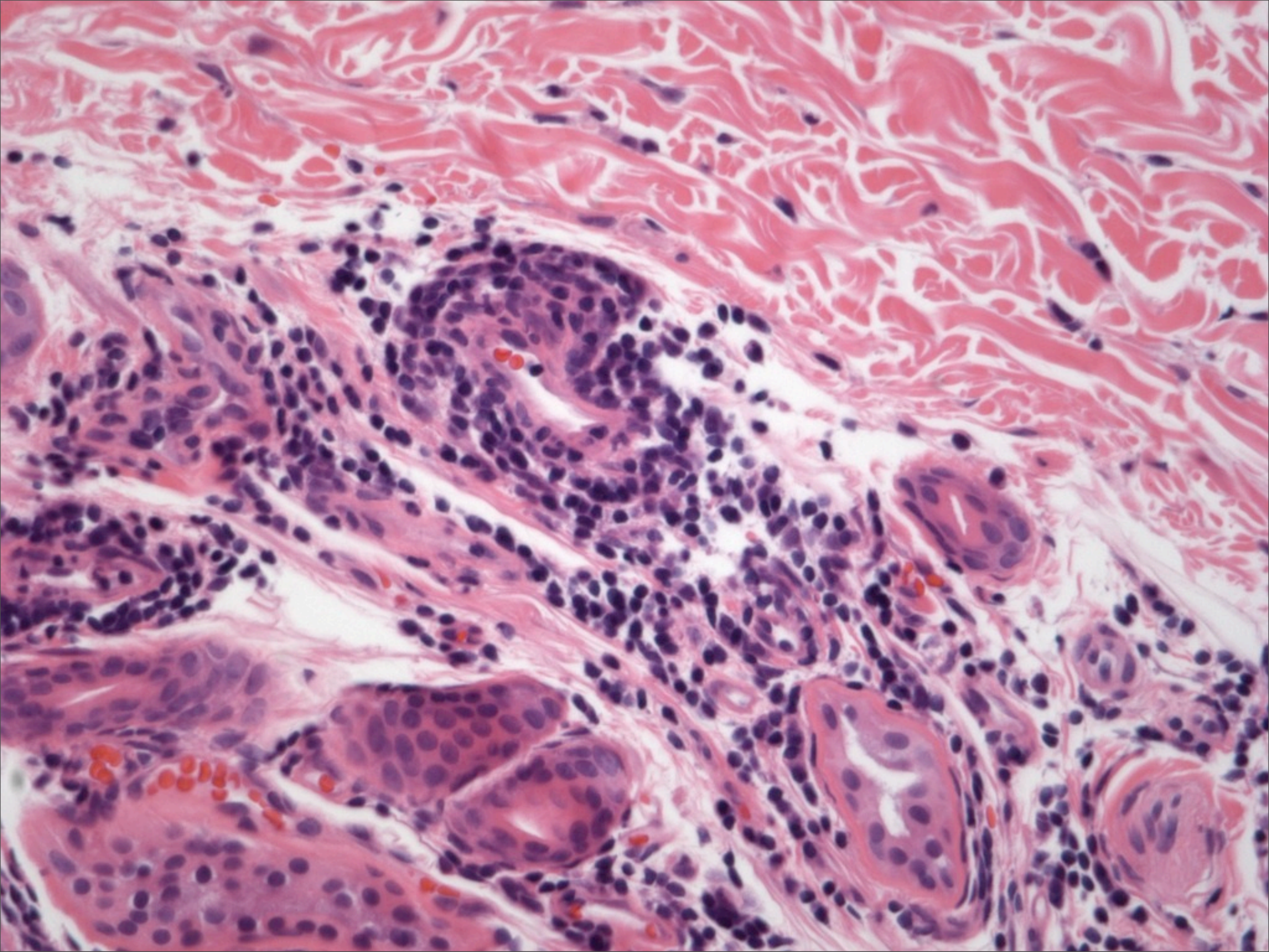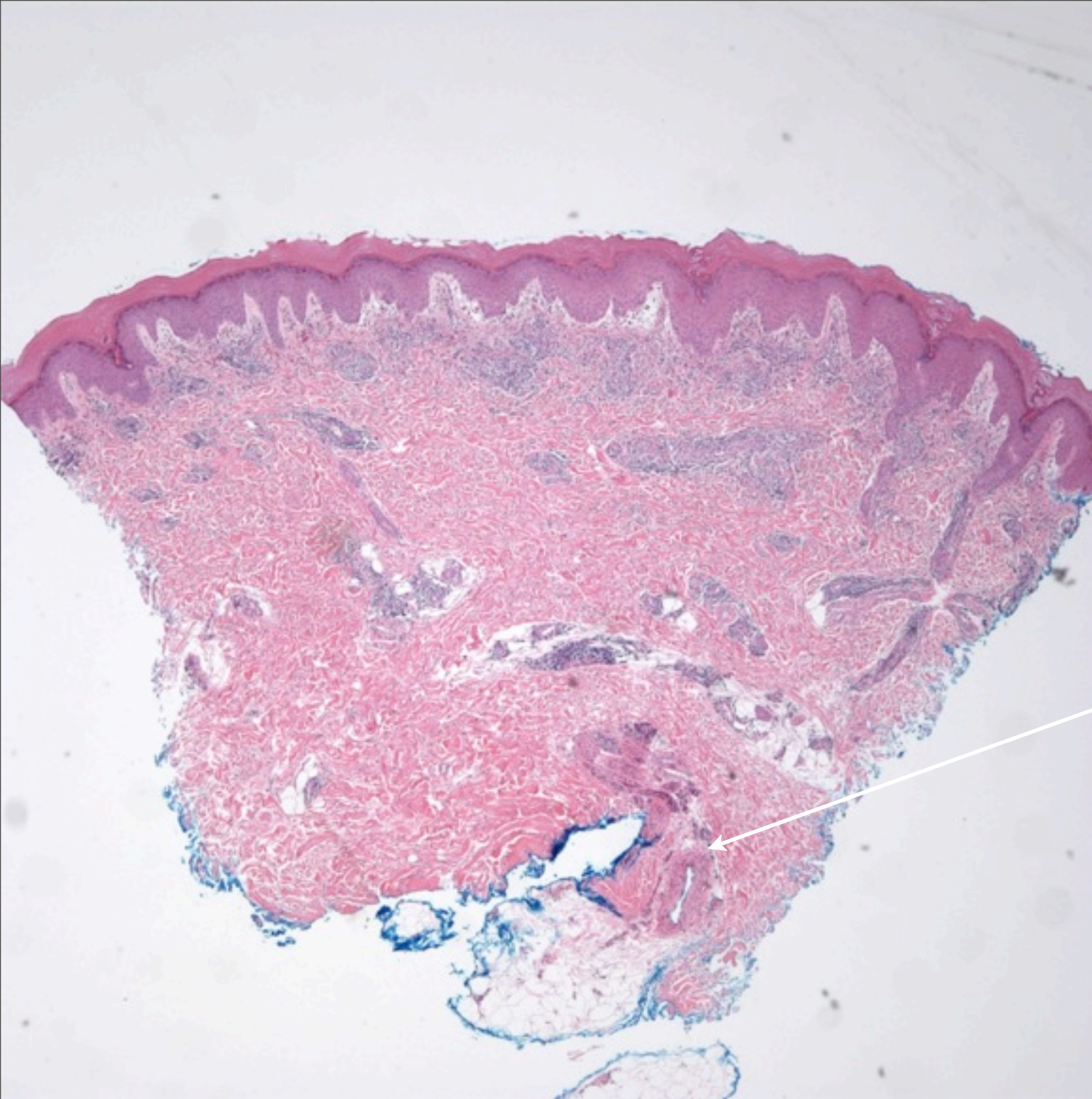


Chillblains (Perniosis)



Variable dermal
mucinosis

May show
lymphocytic vasculitis

Lichenoid interface dermatitis
Superficial and Deep Perivascular
and Periadnexal Lymphocytic Infiltrate